THE UNIVERSITY OF KANSAS
SCIENCE BULLETIN

VOL. XVI.] MARCH, 1926. [No. 5.

The Nature, Origin and Significance of Pigment in Embryos of *Amblystoma*.

HERVEY S. FARIS, Department of Anatomy.

CONTENTS.

PAGE
INTRODUCTION 181
MATERIAL AND METHODS 181
OBSERVATIONS—
A. Pigment in myotomes 183
B. Pigment in central nervous system 189
C. Origin of pigment 194
D. Nature of the pigment 201
E. Disappearance of the pigment 203
DISCUSSION 204
CONCLUSIONS 215

INTRODUCTION.

Although various workers have observed a yellowish-brown pigment scattered through the tissues of amphibian embryos, the writer has been unable to find any satisfactory or comprehensive report in literature concerning it. The purpose of this work is to describe the nature, origin and significance of this pigment in the myotomes and central nervous system of embryos of *Amblystoma*.

For valuable suggestions and criticisms the author is indebted to Professors G. E. Coghill and H. C. Tracy. Furthermore, through grants made to them by the Research Committee of the Graduate School of the University, this work has indirectly profited in a considerable degree.

MATERIAL AND METHODS.

This study has been made chiefly on *Amblystoma microstomun*. The stages of development selected for observation have included those described by Coghill (1916, p. 163) as, (1) embryos that move in response to an electric current, but not in response to tactile

12—2964

stimulation with a hair or other chemically inactive structure, designated the nonmotile stage; (2) embryos taken very soon after there is a perceptible movement in response to tactile stimulation, designated early flexure stage; (3) embryos that move the trunk into a coiled condition, designated the coil stage; (4) embryos that move to the right and left simultaneously in different parts of the body in a sinuous fashion, and have just acquired the power of locomotion, designated the early swimming stage. In addition observations were made on older embryos, the ages of which are indicated by the number of days from the time they began to swim.

Serial sections have been used extensively in these observations. The fixing fluids that have been employed are Bouin's, corrosive sublimate and acetic acid, Van Gehuchten's, Zenker's without acetic acid, Orth's, Kleinenberg's, and formalin solutions. The first two are found to be especially suited to this purpose. Erythrosin and toluidin blue, alum-carmine and Lyon's blue, alum-carmine, hæmatoxylin and orange G, neutral red, and neutral red followed by Janus green, have been used, but alum-carmine has proved to be best adapted for study of pigment in the central nervous system. Hæmatoxylin and orange G show very satisfactorily the relations of the larger structures of the muscle cell, such as the nuclei, yolk globules, and the large masses of pigment which will be described further on in the paper. Neutral red and Janus green are superior for the demonstration of the finer structures of the cell, such as pigment granules, neurofibrils and myofibrils.

Teased preparations and frozen sections of fresh tissue have been used for the study of the nature and origin of the pigment. Preparations have been made by carefully dissecting various tissues such as post-auditory myotomes, central nervous system, cutis, and undifferentiated mesenchyme. These tissues were placed in various stains for different lengths of time. After staining, the larger tissues were teased out on a slide in a drop of the stain and then covered with a cover-glass. By gentle pressure on the cover-glass the tissue was spread thin enough to permit examination under oil immersion objectives. Thinner or smaller pieces of tissue were, after staining, mounted in a hanging drop. Care was taken to use a small drop which would permit the use of oil immersion objectives. The stains used in these preparations were neutral red, Janus green, Nile blue, methylene blue, Sharlach R and Sudan III. Unstained preparations were also studied.

OBSERVATIONS.

A. PIGMENT IN MYOTOMES.

The relation of the pigment to other structures in the cell and its distribution through the myotomes has been studied in corresponding myotomes of the different stages. Serial sections in the frontal plane have been used almost exclusively for these observations.

1. NONMOTILE STAGE.

(Plate XIII.)

The cells in the dorsal portion of the third myotome are not formed into functional muscle fibers, but are radially arranged about the central part. Dorsoventrally there is a progressive change to the longitudinal arrangement of muscle cells containing two or three nuclei. Myofibrils are present in the ventral portion, although obscured by the yolk globules, which are very abundant. In the dorsal portion the pigment occurs in the form of fine granules in the central part of the myotome. These granules are located about the central ends of the nuclei in the radially arranged cells, and around yolk globules. Farther ventrally, the pigment occurs in the middle third of the myotome longitudinally. The pigment granules occur about the nuclei, or the yolk globules, or in strands between these structures. They are more abundant in the ventral portion, and not only occur as fine granules, but also in masses of closely adhering, or segregated, granules. These masses of pigment granules are here termed "pigment bodies." They occur in most instances at one pole of a nucleus. While the pigment bodies appear homogeneous under low magnification, under oil immersion they are resolved into aggregations of granules.

There are very few pigment bodies in the upper third of the myotome. The number increases dorsoventrally through the ventral two-thirds of the myotome. This is illustrated in Figure 1*a*, which is an optical projection of the third myotome, as viewed from the lateral side, showing the number and location of the pigment bodies. The total number of pigment bodies is sixty. The average diameter of thirty of the largest of the pigment bodies is 6.36 micra.

The tenth myotome is less differentiated than the third. The cells in the dorsal region retain their embryonic type and radial arrangement further ventrally than in the third myotome. The nuclei in this more dorsal region are nearly round. In the ventral portion the cells become definitely oriented longitudinally, parallel to the long axis of the myotome. In this region the nuclei are slightly

elongated. No myofibrils can be observed. The pigment through the central portion occurs in the same relative position as in the corresponding region of the third myotome. There are only eighteen pigment bodies in the entire myotome. (Fig. 1*b*.)

The eighteenth myotome is still less differentiated than the tenth. The radial arrangement of the cells about the central portion exists throughout the whole myotome. There are apparently no functional muscle cells. The structure of such a myotome is illustrated in Plate XIII. There are no pigment bodies present. The pigment granules are distributed through the central portion of the myotome about the yolk globules, and around the nuclei they are particularly abundant at the ends which are directed toward the center of the myotome.

2. EARLY FLEXURE STAGE.

(Figure II.)

The third myotome in this stage is more differentiated than the corresponding myotome of the nonmotile stage. The relatively undifferentiated dorsal portion is less in extent. The myofibrils can now be perceived in the middle part of the myotome dorsoventrally in regions where the yolk globules are not too numerous. The differentiation has increased over that of the nonmotile embryo as shown by the elongation of the nuclei and muscle cells, and by the increase of myofibrils. There appears to be relatively less yolk. There is an increase in the amount of pigment. The pigment bodies number 152 in the entire myotome. (Fig. II*a*.) The majority are located near the ends of nuclei. The average mean diameter of thirty of the largest is 8.06 micra.

The tenth myotome has differentiated further than the corresponding myotome of the younger stage. It is less differentiated than the third myotome of the stage under consideration as described above. The undifferentiated cells in the dorsal region gradually change to the longitudinal arrangement in the ventral portion, where the outlines of the cells, the position of the nuclei, and the presence of myofibrils show that the muscle is functional in this region. The yolk globules are more numerous at the ends of the myotomes than in the central part. The pigment granules and bodies have the same general arrangement as in the third myotome. Less pigment is present than in the third myotome, but more than in the corresponding myotome of the earlier stage. This myotome in the early flexure stage contains seventy-one pigment bodies. (Fig. II*b*.) The average mean diameter of thirty of the largest is 7.65 micra.

The eighteenth myotome is more differentiated than the corresponding myotome of the nonmotile stage. In the dorsal third the cells occur in a relatively radial arrangement about the central part of the myotome. The cell boundaries are still indistinct, a condition which characterizes the whole of the corresponding myotome of the younger embryo. There is a gradual transition in this myotome from the radial arrangement of the cells in the dorsal third to the elongated longitudinally directed muscle cells which are characteristic of the ventral third of the myotome. These muscle cells are multinucleated, and each extends the length of the myotome. The pigment in the dorsal portion is distributed in the central part of the myotome as shown in Plate XIII. In the ventral, differentiated portion of the myotome the pigment granules and bodies occur in the central third of the cells. There are only twelve small pigment bodies in the entire myotome. (Fig. II*c*.)

3. COIL STAGE.

(Figure III.)

The third myotome is further differentiated than the corresponding myotomes of the next younger stage, as shown by the increase in the amount of functional muscle in the dorsal portion, the increase in the number of myofibrils, and the elongation of the myotome. There appears to be relatively less yolk. The increase in the amount of pigment is slight. There are 161 pigment bodies present. The average mean diameter of thirty of the largest bodies is 8.12 micra.

The tenth myotome is less differentiated than the third, but is more differentiated than the tenth myotome in the earlier stage. In the dorsal part, the nuclei are crowded together in a transitional stage between the radial arrangement and the elongated cell types. The ventral half of the myotome contains approximately eighty-five per cent of the pigment bodies, which number 150. (Fig. III*b*.) Thirty of the largest of these bodies average 8.16 micra in diameter.

The eighteenth myotome shows a considerable increase in development over the corresponding myotome of the early flexure and nonmotile stages. The middle and ventral portions are differentiated into functional muscle. The pigment granules and bodies have the same arrangement throughout the middle third of the myotome longitudinally, and through the myotome dorsoventrally, as described for the tenth myotome of this stage. There are thirty-five pigment bodies located in the ventral portion in the middle third of the myotome. The average mean diameter of thirty of the largest is 5.9 micra.

4. EARLY SWIMMING STAGE.

(Fig. IV, and Plates XII, XIV.)

The third myotome shows the greatest differentiation of any myotome studied. (Pl. XII.) Cross striations are plainly visible. There is, apparently, a decrease in the amount of yolk as compared with the corresponding myotome of the coil stage. The yolk globules are smaller than in the corresponding myotomes of the younger stages. The number of pigment bodies has increased to 226 as compared to 161 in the coil reaction stage, 152 in the early flexure stage, and 60 in the nonmotile stage. The average mean diameter of thirty of the largest is 8.65 micra. The bodies are typically arranged in the central portion of the myotome at or near the ends of the nuclei.

The tenth myotome is further differentiated than the corresponding myotomes of the earlier stages. There is, apparently, less yolk and a decided increase in the number of pigment bodies. In this myotome there are 364 pigment bodies as compared to 150 in the coil stage, 71 in the early flexure stage, and 18 in the nonmotile stage. The average mean diameter of thirty of the largest is 8.2 micra. The dorsal part of the myotome has many granules, but few bodies. In the ventral part the bodies are numerous, with a relatively smaller number of granules; a similar arrangement prevails in the adjacent myotomes of that region. As the pigment bodies increase in number and size from the dorsal toward the ventral part of the myotome the granules appear to decrease in number until there are only a few in the ventral portion of the myotome, where the pigment bodies become correspondingly more numerous.

A section through the middle of the myotome in frontal plane shows that the nuclei are arranged in three zones. In the outer zones the nuclei are arranged in a single definite row transversely, whereas, in the middle zone they are scattered throughout the middle third of the myotome, but separated from those of the outer zones by a characteristic space, void of nuclei. (Pl. XIV.) The pigment bodies occur at or near the ends of the nuclei of the middle zone and at the inner ends of the nuclei of the outer zones.

The pigment granules are particularly abundant throughout the region between the two outer zones, while the end portions of the myotome contain few granules.

The positions of eighty-one pigment bodies were noted. Fifty-eight, or 71.6 per cent, were at the ends of the nuclei; fifteen, or 18.5 per cent, were at the sides of nuclei, and eight, or 9.9 per cent, of the bodies were located some distance from nuclei. That 9.9 per

cent of the bodies were not in the immediate vicinity of a nucleus may be due to their having been separated from nuclei by the sectioning of the tissues.

The eighteenth myotome is less differentiated than the tenth, as the dorsal portion shows the radial arrangement for a short distance. There are 195 pigment bodies in this myotome (Fig. IV*c*) as compared to thirty-five in the coil stage, twelve in the early flexure stage, and none in the nonmotile stage. The average mean diameter of thirty of the largest is 6.23 micra. The distribution of the pigment bodies is the same as described in other myotomes.

The twenty-fourth myotome shows only a slight degree of differentiation. The pigment granules are distributed around nuclei and yolk globules, similar to the distribution described in the eighteenth myotome of the early flexure stage. In the entire myotome there are only five pigment bodies. These are located within a narrow zone in the middle third. (Fig. IV*d*.)

5. COMPARATIVE SUMMARY.

The numerical relation of the pigment bodies in the third, tenth, eighteenth, and twenty-fourth myotomes is shown in Table I.

TABLE I.—Number of pigment bodies in myotomes.

Stages.	3d	10th	18th	24th
Nonmotile	60	18	....	....
Early flexure	152	71	12	....
Coil	161	150	35	....
Early swimming	226	365	195	5

In the third myotome the number of bodies increases from 60 in nonmotile stage to 226 in the early swimming stage; in the tenth myotome the increase is from 18 to 365; in the eighteenth myotome the number increases from zero to 195, while in the twenty-fourth myotome the increase is from zero to five. The increase in number appears to be slightly retarded in the third myotome after the early flexure stage. This is probably due to the growth, in this region, of the pronephros which prevents the full development of the third myotome, and is the probable explanation of the fact that the third myotome has in the early swimming stage fewer pigment bodies than the tenth myotome.

Table II shows the relative growth in size of the pigment bodies in corresponding myotomes of the four stages.

TABLE II.

THIRD MYOTOME.

	Dorsal	Middle	Ventral	Average
Nonmotile	5.55	6.44	7.16	6.36
Early flexure	6.09	8.79	9.4	8.06
Coil	6.7	8.22	9.45	8.12
Early swimming	6.96	8.06	10.95	8.65
Average	6.32	7.87	9.24	7.81

TENTH MYOTOME.

	Dorsal	Middle	Ventral	Average
Nonmotile	....	....	....	....
Early flexure	6.29	8.19	8.48	7.65
Coil	6.68	8.82	8.99	8.16
Early swimming	6.7	8.83	9.2	8.24
Average	6.58	8.61	8.89	8.02

EIGHTEENTH MYOTOME.

	Dorsal	Middle	Ventral	Average
Nonmotile	....	....	....	....
Early flexure	....	....	....	....
Coil	5.04	6.16	6.5	5.9
Early swimming	5.2	6.49	7.02	6.23
Average	5.12	6.32	6.76	6.06

In computations for Table II ten of the largest pigment bodies were selected for measurement in each of the following portions of the myotome: (1) dorsal, (2) middle, and (3) ventral. The greatest and least diameters were measured in micra and the mean taken. This table shows that there is an increase in size of the pigment bodies from the youngest to the oldest stage, and from the dorsal to the ventral portion of a given myotome. In the middle portion of the third myotome there appears to be a decrease in size from the early flexure stage to the early swimming stage. This may be due to the growth of the pronephros in this region, which by the mechanical factors involved introduces irregularities in development such as shifting of the position of the myotome.

The increase in size in the dorsal part of the third myotome from early flexure to the early swimming stage is from 5.55 micra to 6.96 micra, an increase of 1.4 micra, or twenty-five per cent. In the middle portion of the myotome the increase is from 6.44 to 8.06 micra, which amounts to 1.62 micra, or twenty-five per cent. In the ventral part the increase is 3.79 micra, or fifty per cent. The bodies increase in size dorsoventrally. In the early flexure stage this increase is from 5.55 micra to 7.16, which amounts to approximately thirty per cent. In the early swimming stage the increase is 3.99 micra, or nearly sixty per cent.

6. CONCLUSIONS.

The results of the study of the serial sections show that, (1) the pigment is found chiefly in the central portion of the myotome; (2) the pigment granules are situated about nuclei and yolk globules and extend in strands between these structures; (3) the pigment bodies increase both in number and size from the dorsal to the ventral portion of the myotome; (4) the pigment bodies in corresponding myotomes increase both in number and size with the age of the embryo, at least up to the early swimming stage; (5) the amount of pigment increases as the yolk decreases; and (6) the amount of the pigment varies directly with the degree of differentiation and the development of function.

B. PIGMENT IN THE CENTRAL NERVOUS SYSTEM.

(Fig. V.)

Since there proved to be a distinct correlation between the increase in pigment and the degree of differentiation in the myotomes, the study was extended to the distribution of the pigment in the central nervous system as related to regions of differentiation and proliferation.

Although observations have been made on a large number of embryos, type specimens were selected for a more exhaustive study. The embryos used were in my series designated, No. 304, nonmotile; No. 309, early flexure; No. 308, coil; and No. 302, early swimming. They were all fixed in Bouin's fluid, sectioned transversely five micra in thickness, and stained with carmine. With a projecting apparatus, magnifying two hundred diameters, sketches were made of every fourth section of the nervous system, beginning at the anterior portion of the forebrain. Outlines of the areas of abundant pigmentation were sketched in.

These drawings were continued caudad as far as the pigment could be seen through the projecting apparatus. The drawings were compared with reference to the general distribution of pigment and this comparison was supplemented and checked by direct study of the sections with the microscope. It should be noted that fine granules of pigment occur throughout the central nervous system, but that the regions in which the pigment was especially abundant were indicated by the projection apparatus. The visibility of the pigment through this apparatus thus became a standard for quantitative estimates.

The distribution of the pigment was noted particularly in the rhombencephalon and spinal cord. Different levels were selected for descriptive purposes in order to compare more easily the distribution of pigment in the different stages and to differentiating areas that have been previously described by Coghill (1914, 1916).

Before consideration of these areas and their relations to differentiation, it should be noted that the series of sketches of the sections mentioned above, as well as Figure VIII, were made before areas of differentiation had been taken into account by the author.

1. RHOMBENCEPHALON.

In the rhombencephalon the pigment is located towards the surface in lateral and ventrolateral areas. This occurs throughout the Rhombencephalon and continues caudad in the spinal cord in lateral areas.

(a) *At the Level of the Root of the Trigeminal Nerve.*

In the *nonmotile* stage the rhombencephalon still retains the upright position dorsoventrally. The cells of the inner portion of the rhombencephalon next to the ventricle are epithelial in appearance and arrangement. This structure prevails nearly to the outside of the brain. Here in this region are a few cells that have already differentiated into nerve cells. Their relation to the trigeminal nerve has been described by Coghill (1916, Fig. 20). This lateral and ventrolateral region is the area of abundant pigmentation shown by Figure V, row I and column 1. There is a great abundance of pigment about nuclei and yolk globules. It is most abundant toward the external surface of the brain. There is some pigment along the ventricular surface which probably has been retained from the earlier ectodermal position. There is a large clump of pigment next to the ventricle in the floor plate cells.

In the *early flexure* stage the rhombencephalon has differentiated further than in the nonmotile stage, although there has been only a slight broadening. The area of differentiating neuroblasts is slightly wider in extent. (See Coghill, 1916; Fig. 21.) The pigment is distributed through this area as shown by Figure V, row II, and column 1. The pigment area has increased dorsoventrally, and there appears to be a slight increase in amount of pigment. The largest and heaviest groups of pigment occur toward the outside. In the type specimen from which the drawings were made, there is more pigment immediately along the ventricular border of the

rhombencephalon than in the other specimens. The pigment in the floor plate cells is massed together in the central end of the cells adjacent to the ventricle.

In the *coil* stage the rhombencephalon has broadened so that the areas of differentiation that were lateral in the younger stages are now distinctly lateral and ventrolateral. The cells adjacent to the ventricle are epithelial in appearance and arrangement as in the younger stages, but this epithelial area is less in extent. In this proliferating area there is no increase in the amount of pigment. In the lateral differentiating area there is an increase in the number of neuroblasts. (See Coghill, 1916; Fig. 35.) As the area of differentiation has increased so has the area that contains the pigment in abundance. The pigment extends further toward the ventricle, although most abundant in the outer cells. This is shown in Figure V, row III, and column 1. There appears to be slightly more pigment than in the younger stages at the corresponding level. There is less pigment bordering the ventricle, except the large mass in the floor plate cells.

In the *early swimming* stage there is a further differentiation in this stage over that of the coiled reaction stage. The fiber tracts and differentiating neuroblasts are easily perceived. The pigment is more abundant in the lateral and ventrolateral areas as described in the younger stages. (See Coghill, 1916, Figs. 51-54.) The pigment area has increased in size, however, and is now wider and extends over half the distance to the ventricle. Outside of this area the pigment is not particularly abundant, except in the floor-plate cells, where there is a large mass adjacent to the ventricle. In the lateral and ventrolateral areas the pigment occurs as fine granules. Sometimes under low magnification, some of the pigment appears to be in irregular, stringy masses, but higher magnifications show that they consist of closely adhering granules.

(*b*) *At the Level of the Roots of the Facial and Glossopharyngeal Nerves.*

The areas of abundant pigmentation as described at the level of the root of the N. V. are continuous in the lateral and ventrolateral regions from the root of the N. V. through the levels of the roots of the NN. VII and IX into the lateral areas of the spinal cord.

In the *nonmotile* stage there is apparently less pigment at the level of the seventh than at the level of the fifth nerve and approxi-

mately the same as at the level of the ninth nerve. At the level of the ninth nerve the pigment is in more lateral areas.

In the *early flexure* stage there is an apparent increase of pigment at the level of the seventh and ninth nerves as compared to that of the nonmotile stage. This is most marked at the level of the ninth nerve, which follows closely the increase of differentiation as shown by widening of the rhombencephalon at this level. The extent of the pigment increases correspondingly with the larger area of differentiation. The change in shape of the rhombencephalon at these levels and the increase in extent and amount of pigment is shown in Figure V, rows I and II, and columns 2 and 3.

In the *coil* stage there is a further widening of the rhombencephalon, with an increase in differentiation, and likewise an increase in amount and extent of the pigment. In this stage there seems to be approximately the same amount of pigment at the levels of the seventh and ninth nerves as at the level of the fifth nerve. No increase in amount of pigment could be noted in the proliferating area next to the ventricle. The distribution of the pigment is shown by Figure V, row III, and columns 2 and 3.

In the *early swimming* stage the differentiating areas are wider than in the younger stages, and in a similar way the area of pigmentation is wider and extends more toward the ventricle. The pigmentation is heavier and more pigment occurs in clumps. The greatest amount occurs near the outer edge of the brain. There is approximately the same amount of pigment at these levels as at the level of the fifth nerve. There is no increase in pigment along the border of the ventricle.

2. SPINAL CORD.

The distribution of the pigment in the spinal cord is shown by the projection apparatus to be in lateral areas. The pigment can be traced by this method to the level of the fifth myotome in the nonmotile stage. In the early flexure stage it extends to the level of the eighth myotome; in the coiled reaction stage to the level of the ninth myotome, and in the early swimming stage to the level of the eleventh myotome.

At the level of the third myotome in the nonmotile stage the pigment occurs in the lateral areas as shown in Figure V, row 1, column 4. This corresponds to the differentiating area described by Coghill (1914; Fig. 28). In the early flexure stage there is an increase in amount of pigment in the lateral areas. This is shown in Figure VIII, row II, and column 4. There is no increase in pigment in the

proliferating areas next to the central canal. (See Coghill, 1914; Fig. 29.)

In the coil stage the pigment has increased in extent, as shown in Figure VIII, row III, and column 4. In the early swimming stage there is additional increase in pigment in the differentiating areas as opposed to lack of increase in the proliferating areas. (Coghill, 1914; Figs. 30 and 31.)

This increase in pigment at the level of the third myotome as the embryo develops is distinct. It is even more marked at the level of the eighth myotome. There was no pigment area visible at this level in the nonmotile embryo. In the early flexure stage there was a small amount visible in the lateral area. In the coil stage this area is larger and contains more pigment. In the early swimming stage the pigment has increased in amount and occurs in the area of most extensive differentiation. (See Coghill, 1914; Figs. 32 to 35.)

3. Comparative Summary of Pigmented Regions in the Nervous System.

The definite increase in the amount of pigment could not be measured exactly. The areas of abundant pigmentation, however, increase in size at each of the levels of the neutral nervous system noted in the description. The comparative size of these areas is shown roughly in Figure V. There are no perceptible clumps in the youngest stages, and only occasionally do they occur in the older stages. The amount of pigment in the nonmotile embryo decreases gradually through the rhombencephalon and rostral part of the spinal cord. In the early flexure and coil embryos, the pigmentation increases in the rhombencephalon at the level of the root of N. V., but seems to increase more rapidly at the levels of the roots of NN. VII and IX, until in the early swimming embryo the amount is approximately the same in the lateral and ventrolateral areas at the different levels under consideration.

The increase in amount of pigment and size of areas of abundant pigmentation is more marked in the spinal cord than in the rhombencephalon. Especially is this noticeable at the level of the eighth myotome. The areas of pigmentation can be traced farther caudad as the embryo increases in age.

It is obvious that the areas of abundant pigmentation increase in size with the growth of the embryo, and that there is no increase in pigment in the proliferating areas adjacent to the ventricle. This is true in both the rhombencephalon and spinal cord.

It should be noted that in the youngest stages studied certain cells contain pigment. Coghill (1914) noted that the Rohon-Beard cells in the spinal cord contain masses of pigment. These cells, together with a few motor cells and certain cells in the floor plate, differentiate early, and the pigment, which is probably formed during their differentiation period, is retained in the cytoplasm during the four physiological stages studied.

4. CONCLUSIONS.

From the facts as observed one must conclude that, (1) differentiating areas are areas of most abundant pigmentation; (2) the amount of pigment increases as differentiation proceeds; (3) proliferation is not accompanied by an increase of pigmentation; and (4) prior to the ingrowth of blood vessels the amout of pigment is an index of the degree of differentiation in the central nervous system.

C. ORIGIN OF PIGMENT.

The study of the formation of the pigment in *Amblystoma* embryos has been performed primarily upon fresh preparations of living tissue. Observations have been made not only on the muscle and nervous systems, but also upon preparations from epidermis and undifferentiated mesenchyme. Dissected tissues, both stained and unstained, were mounted on slides and gently mashed under a cover-glass, or placed in hanging drops. Epithelial cells of the skin and undifferentiated mesenchyme cells were mostly used for this work because better preparations can be made from them than from the central nervous system and myotomes; the character of the pigment is the same in either case.

Preparations were kept under observation from one-half to several hours. The longest observations were not continuous, but particular fields were observed at frequent intervals for from ten to fifteen hours.

1. UNSTAINED PREPARATIONS.

Preparations of undifferentiated entodermal cells are better adapted for study of relations of pigment and yolk. The yolk globules vary greatly in size from twenty to thirty micra in diameter to fine globules almost as small as pigment granules. The large globules are motionless. Very frequently the smaller globules exhibit movement which is probably Brownian movement. The movement is more evident in some fields than others. It is not appreciably increased by the use of a warming stage.

Pigment granules occur free in the preparations apart from yolk globules or appear on the surface of globules. Few granules occur on large yolk globules. Medium sized globules frequently have on their surfaces two or more pigment granules. Occasionally a small globule is almost covered with pigment granules. The majority of yolk globules are free of pigment granules.

Pigment granules that are on yolk globules may or may not exhibit movement. Those on the larger globules either do not exhibit motion, or are seen to be gliding over the surface. The pigment granules on medium-sized globules move rapidly over the surface. Pigment granules on some of the smallest globules appear to be more agitated. This movement appears to be increased because the yolk globule is itself in motion. In spite of the moving of the yolk globule and of the pigment granules over its surface, it is very seldom that a pigment granule is seen to detach itself from the yolk globule. The pigment granules that are free in the preparation exhibit movement, which is considered to be Brownian movement. Pigment granules are seen to move from place to place, but this may have been due to the streaming in the preparation. The movement of free granules in certain cells, for example young epithelial cells of the skin, have been seen to move not only by Brownian movement, but also by a jerky vibratory movement which is thought to be similar to the characteristic movement as described by Smith (1920) for pigment granules in embryo chick's eye.

There is no particular change in relation of the pigment to the yolk globules from nonmotile to early swimming stage.

The pigment granules that are associated with yolk are yellow-brownish to brown in color. In the older specimen, preparations were made that contained pigment granules from chromatophores of the skin. These are larger in size and much darker in color than the pigment granules under consideration. There are no pigment granules in the nuclei.

In addition to the pigment granules found in the preparations, there are occasionally fine colorless granules situated on yolk globules. They do not occur in abundance, and it is rare to find many in the same field.

2. NEUTRAL RED PREPARATIONS.

Preparations were made of fresh tissue from *Amblystoma* which had been grown in dilute solutions of neutral red, or of dissected portions of an embryo that were stained in dilute solutions of the dye. After killing the embryo, the tissue was dissected with fine

needles, by aid of a binocular dissecting microscope, and placed in stain diluted by physiological salt solution. Different tissues, such as skin subcutaneous tissue, muscle, and nervous system and of yolk, were placed in solutions of neutral red. The dilution varied from 1:5,000 dilution to 1:40,000. A dilution of approximately 1:20,000 was generally used. The tissues were stained from ten minutes to four hours. Tissues were either mounted on a slide in a solution of the dye, and covered with a cover glass or mounted in a hanging drop. The cover-glass method is preferable for thick tissues such as myotomes, as the weight of the cover-glass spreads the tissue sufficiently to permit light to penetrate the preparation. The hanging drops are preferable for younger stages, particularly for cells of the skin and subcutaneous tissue, as the normal condition of the rounded form of the cells can be maintained and observed. The tissue fragment and the hanging drop in which it was suspended were both necessarily small in order to permit the use of oil immersion lens through all the preparation. Hanging drop preparations are particularly adapted for this work, as air is kept out by sealing the edges of the cover-glass with a mixture of paraffin and vaseline which permits observations for a number of hours.

Embryos of different ages were grown in solutions of neutral red of dilutions from 1:50,000 to 1:200,000. The more dilute solutions were generally used, as the embryos take up the dye very readily. Tissue preparations were made from embryos that had lived two days or longer in the neutral red. The results of the intravital staining were the same as staining fresh preparations of dissected portions.

Observations upon these intravitam preparations of the early swimming stage show the same general arrangement of pigment bodies in the myotomes as found in serial sections, namely, throughout the middle third of the myotome. The pigment granules in muscle cells are located about nuclei and yolk globules and in strands between these structures or free in the cytoplasm. Although the pigment granules were visible in the central nervous system, it was impossible to determine their distribution in the fresh preparations.

In the youngest specimens studied, the epithelial cells of the skin contain much yolk in form of spherules or globules. In these cells the pigment occurs most abundant about the yolk globules in the periphery. The nucleus contains no pigment.

The differential staining of the yolk globules with neutral red and of the relations of the pigment to them is most striking. In prepara-

tions containing groups of yolk globules, the majority of the yolk globules do not stain. The larger globules do not react to the dye as readily as the medium sized and smaller ones. Yolk globules that stain are colored light pink to light red. Occasionally a portion of a stained globule is stained a deeper red. This deeper stained portion often has the appearance of an excrescence or of a ridge usually crescent shaped on the globule. Gradations in staining reactions of yolk globules also occur, as well as differential staining of portions of the same globules.

There are occasionally granules on yolk globules that react to the dye. These are stained differentially from bright red to a deep red. These granules no doubt are identical with the "beta" bodies as described by Coghill (1915). These granules glide over the surface of yolk globules. Some of the dark-stained granules have been observed to leave a globule, and when free in the preparation exhibit the Brownian movement, and they cannot be distinguished from the free-pigment granules. The pigment granules, whether free or in a group, appear to stain a very deep red.

While the majority of the observations were performed on preparations from undifferentiated entodermal cells, these observations were corroborated with evidences found in preparations of other tissue cells. Epithelial cells from skin of young embryos of nonmotile stage show the same differential staining of yolk and of neutral red granules with reference to pigment. In such a cell, the structures are more compact. A larger percentage of yolk stains. There are more smaller globules that have neutral red granules or pigment granules exhibiting a vibratory gliding motion over the surface. The nucleus does not stain, or contain pigment granules.

The minute colorless granules observed in unstained preparations were not seen in neutral red preparations. Melanin pigment granules from chromatophores of the older stages sometimes were included in the preparations. The melanin granules from chromatophores are larger and do not stain with neutral red. They are dark brown in color. Small yolk globules slightly larger than pigment granules occur in some fields and do not react with the neutral red.

3. JANUS GREEN PREPARATIONS.

In preparations stained by Janus green the yolk globules do not stain readily. The small number that react to the stain are light greenish-blue in color. Upon the surface of some of these yolk globules are granules few in number that are stained by the Janus

green. These vary in form and location. They may appear singly or as a row or ridge of fine granules. These granules, no doubt, are the "alpha" granules described by Coghill (1915). Granules were observed to leave the globules, but not frequently. When they do leave they cannot be distinguished from similarly stained granules in the preparations which are probably mitochondria, since Janus green is a specific stain for mitochondria. Mitochondria are not present in large numbers, nor were they observed to develop into pigment granules. The pigment granules are not stained by Janus green.

In some preparations there are occasionally globules that have a pinkish tinge, in whole or in part. This probably is due to reduction of the dye as noted by Coghill (1915). Cowdry (1914) also mentions that reduction of Janus green produces such a change. The change of granules from greenish blue to the pinkish purple color has not been observed. (Coghill 1915.)

4. Neutral Red and Janus Green Preparations.

The use of neutral red and Janus green as a double stain is in the main in agreement with Coghill (1915). The globules stained with green are the same as those which he called "alpha" globules. In a preparation of yolk in which the "beta" globules are most numerous I saw a group of four "alpha" globules that were pink in part. Three of them had green-colored granules on the surface which were probably "alpha" granules. Further observation showed that the pink portion of one of them was increased. This may have been due to turning of the globules, but may have been caused by reduction of the dye. During the period under observation, none of the granules were seen to leave globules. However, the dark red "beta" granules observed on the red-colored "beta" globules have been seen to leave the globules, and when this occurred they could not be distinguished from the pigment granules free in the preparation.

Sometimes preparations from skin of the younger stages would show very well the action of the two dyes. In a hanging drop, epithelial cells retain a rounded or oval shape; the nucleus is excentrically placed; the yolk globules are very numerous, and pigment granules scattered through the cytoplasm. The nucleus does not stain. There are more "beta" globules. Some of the "beta" globules have "beta" granules on their surface. Excrescences occur on some "beta" globules. The dark colored "beta" granules cannot be distinguished from the pigment granules free in the cytoplasm. The

pigment granules stain a deep red. They are more numerous in the periphery of the cell. Brownian movement occurs to a limited degree. "Alpha" granules were seen, but are not numerous. In these cells a larger proportion of yolk globules stain than in a preparation from the entoderm. Also, there is more pigment in proportion to the amount of yolk. There is no pigment in the nuclei. Greenish "alpha" granules have not been seen to change into pigment granules.

5. METHYLENE BLUE PREPARATIONS.

Methylene blue was used very few times. It did not react uniformly through the preparations. In some fields the dye would stain a few of the yolk globules. In such a group the granules on their surfaces and the pigment granules free in the preparation appeared to stain a deep blue. It was thought that these yolk globules that reacted to the stain may have been "beta" globules, and that the granules that were stained on their surfaces may have been "beta" granules. In the fields where the stain reacted, no colorless granules were seen.

6. NILE BLUE PREPARATIONS.

Nile blue was used as a stain for the dissected fresh material from embryos of different ages, and as an intravitam stain. Nile blue, even when used in very dilute solutions, was apparently too toxic for normal growth. In different groups placed in the dye, from one-fourth to all of the specimens died in a few hours. Portions of entoderm, muscle and skin, dissected from stained specimens, were examined. The yolk globules stain differentially, some deeply, but most of them lightly. The muscles do not react readily to the stain. Granules, assumed to be "beta" granules, reacted to the stain. Within some groups of granules there seems to be a gradation of color from a lighter blue to an intense blue. The pigment granules, free in the preparation, stained a dark, intense blue. Melanin granules, from chromatophores in the skin preparations, did not react to the stain, or only slightly. By changing the focus some of the melanin seemed to have a greenish tinge. This may have been due to diffraction or slight adhering of the dye to the granules.

Fresh preparations from living embryos react to Nile blue very readily. Dilutions from 1:50,000 to 1:60,000 were generally used. The nuclei do not stain. Nearly all the yolk globules react to the dye, although some deeper than others. Pigment granules stain a very deep blue, so dark as to appear almost black. In some prepara-

tions there were free yolk globules that stained differentially. Deep blue granules were observed to be on the surfaces of some of the yolk globules and many of them exhibit gliding vibratory movement. This was most active on the smaller globules. Only one granule in these Nile blue preparations has been seen to leave a globule, and it then had the appearance of a free pigment granule. From the staining of the granules and yolk it seems that Nile blue stains the "beta" globules and "beta" granules. No colorless granules were observed.

7. PANCREATIN DIGESTION EXPERIMENT.

The undifferentiated entoderm was removed from several embryos by careful dissection, with particular attention not to include an undue amount of pigment from the skin. Portions of the tissue were placed in a solution of pancreatin, and digested in an incubator for a number of hours. Others were incubated in physiological salt solution alone. Portions of the mixture were removed at intervals of from six to forty-eight hours and examined, both unstained and stained, for evidences of production of granules by the action of digestive enzymes.

The appearance of the unstained digested preparations is very much the same as the unstained preparations examined immediately after removal from the body of the embryo. The yolk globules vary in size. There were some colorless granules on yolk surfaces, but there was apparently no increase in amount over normal conditions. Very few pigment granules were present and they were mostly free in the preparation. There was no apparent increase in number of pigment granules due to digestion. The pigment granules were most numerous in fields containing many small yolk globules.

The use of neutral red did not show an increase in amount of pigment. However, it appears that more of the yolk stains than in living preparations. The smaller globules seem to take the stain more readily than the larger ones. The excrescences and "beta" granules occur in very much the same way in incubated undigested as in digested preparations. In both preparations there was apparent differential staining of granules on the surfaces of globules from a lighter red to the dark red of the pigment granules.

Nile blue presents a similar picture. The majority of the yolk globules stain. The smaller globules stain deeper that the larger ones. More deeply stained granules occur on the surfaces of the smaller, deeply stained yolk globules. There was apparently no increase in number of granules. Sharlach R reacts in a similar way.

The pigment granules stain slowly to a deep red. The yolk stains differentially. The smaller globules stain more deeply than the larger ones. The granules on the surfaces stain deep red.

The pancreatin digestion experiment did not show an increase in amount of "alpha" or "beta" granules. It did show, however, that the action of the digestive enzymes on the yolk globules prepared more of them for staining. It appears that the action of pancreatin occurs most rapidly on the smallest globules.

8. CONCLUSIONS.

The work on the origin of the pigment shows the following: (1) presence of colorless granules in unstained preparations; (2) differential staining of yolk globules and of granules on their surfaces; (3) the pigment granules are formed in the cytoplasm; (4) the pigment does not come from the nucleus; (5) the differential staining of granules on the stained yolk globules indicates that the pigment is formed from substances in the cytoplasm, part of which may be liberated during the process of digestion of the yolk.

D. NATURE OF THE PIGMENT.

The pigment in the differentiating tissues of the embryos studied is not in sufficient quantity to permit separation from the tissues. For this reason a chemical analysis has not been made. Microchemical tests for the study of pigment in tissues are now being standardized, as shown by the work of Hueck (1912), Dolley and Guthrie (1918, 1921), Schmidtmann (1920) and others.

1. STAINING REACTIONS IN FRESH PREPARATIONS.

Various stains have been used on fresh tissue to observe the reaction of the dyes on the pigment. Neutral red, methylene blue, Nile blue, Janus green and the fat stains, Sudan III and Sharlach R, were used.

The pigment granules, yellowish brown to brown in natural condition, stain with neutral red, Nile blue and methylene blue.

In preparations from the older specimens the pigment from the chromatophores were frequently included. This pigment is easily distinguished from the pigment in the differentiating tissues by difference in size and color of the granules. The pigment in the chromatophores stain very slightly with neutral red and Nile blue and not at all with Janus green. This pigment is melanin elaborated by specialized cells. Fat stains do not stain it.

The fat stains, Sudan III and Sharlach R, were used primarily in an attempt to determine the relations of the pigments to fat. The results were the same in both cases, although Sharlach R was the more commonly used. Preparations were stained similarly as with the other stains. Yolk globules stain differentially; some a very light red; others a deep red. Portions of some globules stained deeper than the remainder of the globules. The majority of pigment granules occur about the deeper stained yolk globules. The granules on the surface of the deeper-stained globules seem to stain with approximately the same intensity as the globules. The pigment granules, free in the preparation, appear either to have actually stained or the stain has saturated the surrounding tissue, and thus causes the granules to appear darker. Biondi's stain, containing osmic acid, was used, with the result that the pigment granules are blackened by the osmic acid and retain the color through paraffin imbedding.

2. Staining Reactions in Sectioned Material.

The observations on the distribution of the pigment have been on sectioned material stained with various histological stains. Such stains as eosin, erythrosin, orange G, and Lyon's blue do not react with the pigment. Other stains appear to act very weakly at times. This was observed with methylene blue, neutral red and Nile blue. Such reactions are very slight. They appear to be a physical combination only. The pigment does not stain with alum-carmine and Janus green. It seems to be affected by imbedding in paraffin after alcohol-xylol treatment as shown by the weaker staining reactions with neutral red and Nile blue.

3. Solubilities.

The routine procedure has been to fix tissue in ordinary fixing solutions, carry it up through graded alcohols and clear in cedar oil or xylol and imbed in paraffin. The pigment does not disappear from the tissue. More powerful fat solvents were used than alcohol, such as chloroform, acetone, ether and xylol. After prolonged treatment of twenty-four hours or longer the pigment did not disappear, or only very slightly. Dolley and Guthrie (1921) state that lipochrome or fat-holding pigment will disappear from tissue after treatment of one-half hour in absolute alcohol. There was no appreciable disappearance of pigment after such treatment, even if tissues were kept in absolute alcohol from two to four hours.

4. VARIOUS OTHER TESTS.

Hydrogen peroxide and ferric chloride oxidized the pigment and changed it to a colorless state after a few hours. The pigment of the chromatophores also is bleached by the oxidizing agents.

The pigment gives a negative iron reaction to ferrocyanide of potassium followed by acid alcohol. This is true also of the melanin of the chromatophores. The pigment is insoluble in dilute acids, alkalies and ammonia water.

5. SUMMARY AND CONCLUSIONS.

Since the pigment reacts with fat stains, it seems to be necessary to class it with fat-holding pigments. The fat solvents, however, which dissolve fat-holding pigments, called lipochromes, do not remove this pigment appreciably, so that in tissues prepared with histological methods it presents characteristics of melanin.

E. DISAPPEARANCE OF PIGMENT.

The study of relation of pigment to differentiation has been confined to the early swimming and younger stages, because during this period blood vessels have not entered the myotomes and central nervous system. Soon after the embryo swims the blood vessels are in close proximity to the brain and rapidly come in contact with it and later with the spinal cord. Before the feeding stage blood vessels can be seen between the myotomes. This added factor of blood vessels connected with the tissues to serve in nutrition and excretion necessitated a study of its effect on the amount of pigment.

In order to determine whether this pigment is distinctly of embryonic nature, tissues from several adult *Amblystoma* have been examined. It was found that the pigment had entirely disappeared from skeletal muscle. The same is true also of adult muscle of *Rana pipiens*, *Necturus* and *Bufo*. Serial sections have been studied of several embryos older than the early swimming stage to observe the time and method of the disappearance of the pigment.

In an embryo approximately two days older than the early swimming stage the pigment has the same general distribution as described for the early swimming stage. An exact count of the number of pigment bodies in muscle at this time has not been made, but there is no apparent difference from the younger stage. Four embryos were observed that had just attained the feeding stage. At this time blood vessels can be seen between the anterior myotomes. In these myotomes the relations of the pigment in the cells

have changed. Many of the pigment bodies are irregular in shape and appear to be breaking up. The pigment bodies are not confined to the middle third of the myotome longitudinally. A few are now situated in the end region between the nuclei and the end of the myotome. Very frequently these bodies were situated close to the blood vessel. In a few instances pigment bodies were seen in a blood vessel. Although there appears to be a migration of pigment bodies or fragments of pigment bodies toward the blood vessels this occurs comparatively slowly.

In embryos two, seven and fifteen days older than the feeding stage there is progressively less pigment in the myotomes. The pigment begins to disappear first in the anterior myotomes, and its disappearance proceeds caudad. In serial sections of portions of myotomes in *Amblystoma* larva 38 mm. in length, a few pigment bodies occur near the ends of some nuclei. Pigment granules are occasionally seen near the pigment bodies. The pigment is not abundant. Its complete disappearance occurs between this age, which is approximately six weeks after feeding, and metamorphosis. The pigment seems to be removed from the myotomes through the blood. This phase of the problem demands further study.

DISCUSSION.

In this discussion of the writer's results in the light of the work of other investigators, the pigment, with which this paper is concerned will be considered with reference to (1) its origin, (2) its nature and (3) its significance.

A. ORIGIN OF THE PIGMENT.

The pigment described in differentiating tissues of *Amblystoma* occur in cells that are particularly adapted for study of pigment formation. Not only is this true for study of the origin of the pigment, but also for the study of intracellular metabolism, since each cell from the beginning has food, in form of yolk, sufficient for growth, differentiation and embryonic function. During the period under consideration there are no blood vessels in the tissues concerned to serve in nutrition or excretion. During this period of development, before the blood vessels enter the tissues, each cell of the tissues must produce all necessary enzymes for its absorption of the yolk and for the metabolism of differentiation and proliferation. Some enzymes or hormones must prepare the yolk for as-

similation similarly to the process of digestion; other enzymes must aid in the physiochemical reactions of metabolism.

Since these cells are thus adapted for study of intracellular digestion, assimilation and metabolism, they have been particularly examined for evidence concerning the place and mode of formation of the pigment that occurs within them.

Various workers, such as Von Szily (1911), Schultz (1912), Wagner (1910), and Dyson (1911), hold to the view that the pigment arises in nuclei. The writer finds no evidence that the pigment is produced by the functional activity of the nucleus. No pigment has been observed either in the nucleus or imbedded in the nuclear membrane. Observations in the younger cells, especially in the muscle sections, show that pigment granules occur on the surface of the nuclei, but there is no evidence that it came from nuclear material. No extrusion of granules from the nucleus, colorless or pigmented, have been observed. In no phase of the work have nuclei in pigmented cells appeared shrunken or degenerative.

According to Child (1915) "undifferentiated protoplasm is protoplasm reduced morphologically to its lowest terms." The embryonic cells under consideration are morphologically simple. The most conspicuous structures in the cytoplasm are the yolk globules, which are so numerous that they hinder the observations of the relatively permanent structures that are formed in the cells. Observations have been made on both unstained and stained preparations to observe the possible presence of chromogen and its transformation into pigment. The two possible sources for the chromogen are (1) mitochondria, and (2) other substances in the cytoplasm.

Some authors, such as Champy (1911) and Luna (1913), have described the formation of pigment from mitochondria. Mitochondria are not present in large numbers in embryos of *Amblystoma*. This was noted by Coghill (1915) and was verified in the present series of experiments by the use of Janus green. This dye, which is a specific stain of mitochondria, stained certain granules on the surfaces of yolk globules, as was noted in the observations. These granules may develop into mitochondria, but this has not been positively demonstrated. At no time has the stain reaction of these granules and of mitochondria suggested that mitochondria develops into pigment.

The chromogen of the pigment seems to arise in the cytoplasm as colorless granules on surfaces of yolk globules. These colorless granules are observed in the unstained preparations, but are not observed

in preparations stained by various dyes. The use of neutral red, especially, shows a differential staining of granules on yolk globules from a light to a dark red. The darker granules when they detach themselves from the yolk cannot be distinguished from pigment granules free in the preparation. The size, position and staining reactions of the granules on the surface indicate that the colorless granules are the chromogen of the pigment granules and that they arise on the surfaces of yolk globules. This does not exclude the possibility of the formation of the chromogen in the cytoplasm apart from the yolk globules. In fact such an origin is suggested in the serial sections of the youngest embryos, where the pigment was observed particularly in the vicinity of the nuclei. In those cells the physiological activities naturally occur near the nucleus and the action of the cell ferments converts the chromogen into pigment. Later the chromogen probably is formed faster than it becomes pigmented as suggested by Smith (1920), thus explaining the presence of colorless granules. Smith notes that the pigment in the embryonic chick's eye develops first as a colorless chromogen and later becomes colored.

The nature of the chromogen is debatable. As has been cited in literature, pigment may come from a number of substances. In the production of melanin, different workers such as Bertrand, Gessard, Durham, and Block have shown that such compounds as tyrosin, tryptophane, 3-4 dioxyphenylalanin, epinephrine, occur in tissues in sufficient quantities for the production of the pigment. The cell ferments are formed by the nucleus. Whipple (1921) concludes that substances containing the pyrrol group are essential for formation of hemoglobin and bile pigments. Melanin on decomposition yields compounds containing the pyrrol group. It is probable that substances such as tyrosin and pyrrol derivatives arise during the differentiation of the cells in the embryo of *Amblystoma*.

As the young cells contain a nucleus, relatively undifferentiated cytoplasm and food in form of yolk, the substances that enter into the formation of the pigment must be produced through the digestion of the yolk or as a result of metabolism. Or they may be formed by a combination of both these processes. As has been noted in the observations the pigment is formed in the differentiating tissue. So that whenever, in the process of differentiation, substances capable of forming pigment are produced in excess chromogen might be the result.

Some of these substances no doubt are formed from the yolk during its digestion. The differential staining reactions of the yolk globules by neutral red and Nile blue show that physiological processes occurring on the surface of the yolk produce or liberate certain substances that stain more readily than the yolk globule as a whole. The digestive enzymes present may break up the yolk into the amino acids which in turn are used in building up the protoplasm of the cell. As the yolk is the same for all cells, then those cells which are differentiating the most rapidly, may not have use for all the constituents of the yolk and it would be these substances that are produced in excess which may enter into the formation of chromogen. Since during the early embryonic period in *Amblystoma* there are no blood vessels in the muscles and nervous system these substances must remain within the cells that produce them.

The writer has made no attempt to determine the chemical composition of the yolk. McClendon (1909), working on centrifuged frog eggs, was the first to attempt the chemical analysis of yolk. He concludes that it consists of some fat, considerable lecithin and a large quantity of protein. He considered the protein to be a nucleo protein as it was rich in phosphorus. Jenkinson (1914) reports on the composition of yolk of frog's eggs, and considers the protein to be a globulin or nucleo-protein and that a purine base, which probably is xanthine, can be obtained. He points out the difficulties of chemical analysis even in quantities of the yolk and the impossibility of such analysis of a single egg. Nevertheless these investigators have shown the presence in the yolk of proteins that can be broken up into amino acids and synthesized into body protein. It is believed, therefore, that the yolk of *Amblystoma* is of such composition that pigment-forming substances can be derived from it during its digestion.

The writer's observations upon the origin of this pigment have been performed on the epithelial cells of the skin rather than upon those of the entoderm, since the ectodermal cells show a greater degree of differentiation. The metabolic rate is presumably higher in cells that are differentiating more rapidly, and it is in these rapidly differentiating cells that the pigment increases at the most rapid rate.

Whipple (1921), after a review of the various factors involved in the metabolism of bile pigments, has evolved a new working hypothesis as an explanation of the metabolism of pigment. The es-

sential feature of this hypothesis is the "pigment complex," which he describes as a "group of substances which are essential parts of the mature body pigments." Whipple believes that experimental evidences show that the "pigment complex" is formed from substances obtained from (*a*) food, (*b*) body cells, and (*c*) hemoglobin. Formed from the "pigment complex" are hemoglobin, bile pigments and, possibly, urobilin and urochrome. Whipple (1921) holds that the pyrrol group seems to be the essential factor in the chemical composition of the substances in the "pigment complex."

In these cells under consideration, it has already been suggested above that the pigment may come from substances derived from the food. It is also probable that other substances are formed during metabolism which enter into the formation of this pigment. These substances formed by metabolic processes could, if there were vascular and excretory systems, be carried out of the tissues and either utilized by different organs of the body or excreted, but in the absence of circulatory systems the substances that are probably comparable to Whipple's "pigment complex" are necessarily retained within the cell.

The waste products from metabolism may be formed in either the anabolic or catabolic phase of metabolism. The anabolic phase involves the building up of complex elements out of more simple molecules. Macleod (1922) states that chemical transformations that occur in the cell are difficult to obtain in the chemical laboratory. He says: "For in the cell these chemical transformations are capable of being guided to a very remarkable degree of nicety so as to produce intermediate products that are used for some special purpose, either by the cell that produced them, or after transformation by the blood, etc., by cells in other parts of the organism." Such products, which Macleod calls intermediate products, the writer considers, enter into the formation of pigment in *Amblystoma* embryos In this inert condition they are retained within the cell until the tissues are penetrated by the vascular system.

Many workers have shown that waste products of many tissues have been formed into pigment, and recently Whipple (1921) has shown that substances from the breaking of the body protein enter into the "pigment complex," from which bile pigments and hemoglobin are formed. Thus in the differentiating tissues of *Amblystoma* embryos substances formed during the catabolic phase of metabolism probably enter into the formation of the pigment. As soon as the tissue begins to differentiate, the building up and tearing

down of the protoplasm begins. The substances from the wear and tear of tissue cannot be eliminated, and thus enter into the formation of the pigment.

The group of substances mentioned above that are formed during the differentiation and embryonic function of the tissues under consideration might well be regarded as a "pigment complex." By "pigment complex" is meant in this connection a group of substances that are formed in the differentiating tissue from three probable sources, as follows: (1) Excess of substances formed during digestion of the yolk that are not needed by the tissue cells; (2) intermediate products of building up of the protein during the anabolic phase of metabolism; and (3) products of breaking down of the cell protein. It is considered that as the substances accumulate they are converted by activity of the cell into pigment. The colorless chromogen as precursor of this pigment probably is laid down, then the color develops in it. This would account for the presence of the colorless granules which appear to be changed into pigment.

B. NATURE OF THE PIGMENT.

The pigment in differentiating tissues of embryonic *Amblystoma* does not occur in sufficient amounts to allow isolation from the tissues. A chemical analysis of it, therefore, could not be made. In order to determine the nature and classification of the pigment it was necessary to depend upon microchemical methods.

This pigment is a waste product of normal metabolism and has many characteristics in common with the waste pigments found in the human body. Lubarsch (1902) and his pupil Sehrt (1904) found a waste pigment in different parts of the human body which they called lipochrome. Lubarsch advanced the theory that the lipochrome is a byproduct of metabolism. Sehrt observed that the pigment in the tissues nearly always gave strong reactions to fat stains in fresh preparations and only weakly or not at all after treating with alcohol and imbedding in paraffin. He does not recognize the possibility to two kinds of pigment being present. Other workers have noticed the fat-staining characteristics and partial solubilities of waste pigments. Hueck (1912) found that "wear and tear" pigment reacts to Sudan III, Sharlach R and Nile blue. He believes the reaction of Nile blue is characteristic for fatty acids. Hueck suggests the possibility that "wear and tear" pigments are products of fat metabolism. Ciaccio (1915), working on auto-oxidation experiments of lipoids found that unsaturated fatty acids are oxi-

dizable and undergo important changes of color, consistency, solubility properties, and reactions towards alkalies and acids, whil they retain their natural characteristics to react toward fat stains He distinguishes two types, one derived from phosphatids whicl react weakly towards fat stains, and the other derived from fatty acids which react intensely with Sudan III and Sharlach R Schmidtmann (1920), after extensive study of sectioned materia from brown atrophy of the heart, concludes that the pigment whicl is present in sectioned material is melanin, because it does not diffe in staining reactions and solubilities from melanin. Schmidtman does not believe that it is a metabolic product of fat, but that th staining of the pigment granules in fresh tissues indicates that ther is a mixture of fat with the pigment of more or less accidental na ture and that there is a connection between nutrition and fat con tent of pigment.

Recently the biochemical and physiological studies of Palmer an Eckles (1914) and Palmer (1919) have demonstrated that the plan pigments carotin and xanthophyll are widely distributed in ani mals and are intimately connected with animal metabolism. Th carotinoids (carotin and xanthophyll) were found to be identica with the pigments in blood serum, skin, corpus luteum, milk, an in the body fat of the cow, horse and hen. There is a remarkabl species difference. Color is produced after feeding foods contain ing carotinoids, but it disappears if deprived of the pigments.

Dolley and Guthrie (1921) find that the pigmentation of brow atrophy of the heart consists of not only the lipochrome usuall ascribed to it, but also a melanin, which is a waste product. The believe that the lipochrome is derived from plant carotinoids an carried to the heart by the blood, while the melanin is "an endoge nous pigment derived from disturbed metabolic processes."

Although it was formerly held that waste pigments are lipo chromes of animal origin, recent workers, such as Palmar an Eckles, Schmidtmann, Dolley and Guthrie, have shown the presenc of two waste pigments, one a melanin of endogenous origin and th other a lipochrome derived from the plant carotinoids in the food.

The reactions of the pigment in the differentiating tissues o *Amblystoma* in sectioned material agree with the characteristics o melanin. It stains only slightly with fat stains or basic dyes. It is iron free. It persists in sectioned material after imbedding in paraffin. A very small portion, if any, of the pigment is dissolved by fat solvents. The objections to classifying the pigment as

melanin are two, namely, (1) the staining reactions in fresh preparations, and (2) the presence of the pigment in tissues which do not ordinarily elaborate melanin.

Various stains were used in fresh preparations to determine the nature of the pigment. It has been already noted that the colorless granules, which are believed to be the chromogen, and the pigment granules, react positively to Sudan III, Sharlach R, Nile blue and neutral red. This indicated that the granules, chromogen and pigment, are either related to fat metabolism or intimately mixed with the fat or fatty acids in the cytoplasm.

It is plausible that metabolic products of the fats and fatty acids form colored compounds, according to the work of Ciaccio. The yolk contains fat which undoubtedly is used in the reactions of the metabolism. If intermediary products of metabolism of fat or end products formed that are not needed in the cell they may contribute to the chromogen of the pigment. That pigments in animals are formed directly from fats has so far not been proven.

The writer is of the opinion that the mixing of the fats and fatty acids of the cell in a physical manner with the pigment accounts for the positive staining reactions with fat stains in fresh preparation. That this might be possible has been suggested by various authors, such as Dyson (1911), Hueck (1912), and Schmidtmann (1920). The writer's study of the relation of fats to the pigment was not carried further than the use of the fat stains. The same pigment granules that stain with fat stains in fresh preparations react only very slightly to them or to basic dyes in sectioned material. This could easily occur as the alcohol used in dehydration of the tissue would extract the fat.

The writer does not believe that the waste pigments should be classified as melanin without further study. Schmidtmann (1920) and Dolley (1921) state that the pigment in brown atrophy of the heart is melanin because it gives many of the microchemical reactions of melanin. If this pigment is considered melanin it destroys the general conception of the majority of workers that melanin is a product of specialized cells produced for a particular purpose. It seems more reasonable that the pigment formed in the heart from metabolic products by the activity of the cells would not be found there if the interchange of products of the cell and substances in the blood plasma were normal. If these same substances that form pigment where the circulation is impaired were normally carried from the tissues, then they might be regarded as substances that occur

in the "pigment complex" of Whipple. The writer believes that in the differentiating tissues of *Amblystoma* the substances which form the pigment are comparable to those substances in Whipple's "pigment complex."

It may be shown in the future that the substances that are used in the formation of melanin are at least a part of the substances in the "pigment complex." Further work is needed on pigment metabolism to show the relation of the substances from which melanin is formed to those substances from which hemoglobin and bile pigments are derived.

The waste embryonic pigment in *Amblystoma* is derived primarily from metabolic products of protein metabolism and food, and is intimately mixed with fats, probably physically and not chemically. This pigment is comparable to bile pigments, since it is a waste product. In certain other features it resembles melanin, but it cannot be unconditionally classified either as melanin or lipochrome. In certain specialized cells it may be retained and further differentiated into melanin in definitive organs.

C. SIGNIFICANCE OF PIGMENT.

Any classification of this embryonic pigment would mean very little if the relation of the pigment to the tissue were not considered in the terms of the life of the whole organism. In other words, the significance of the pigment can be understood only as it is considered in the light of the principles underlying the development of the embryo as a whole.

A few investigators of different amphibian eggs and embryos have offered suggestions concerning the probable significance of the pigment. Bellamy (1919), from his studies, said: "It may be noted here also that pigment appears more densely in the most active regions of the egg where other evidences indicate that oxidations are proceeding more rapidly than elsewhere. In other words, the density of pigmentation seems to be an expression of the rate of at least certain oxidations occurring in that region." He suggests that increased pigmentation is related to regions where cell division is most rapid. Jordan (1893), from observation on the newt, suggested "that the pigment marks physiological activity, and that the less heavily pigmented cells of the ventral wall of the archenteron owe their relative lack of pigment to more sluggish metabolism attendant upon less rapid cell division." King (1902), working on the egg of *Bufo lentiginosus*, doubts the probability that pigment increases with rapid cell

division, for, she says, "It is certainly true that the large yolk cells in the egg of *Bufo* divide less frequently than the cells in the upper hemisphere, but there is no evidence that the deeply pigmented cells of the outer surface of the upper hemisphere or of the dorsal wall of the archenteron divide more rapidly than the cells that are found between them."

While the observations of the above-mentioned investigators were incidental to their work on other major problems, in the writer's studies which concern pigment particularly, it is found that pigment makes its appearance as a result of "oxidation processes" or "physiological activity" in early embryos of *Amblystoma*, but it is obvious that there are more remote factors in pigment formation than simply "oxidation" or "physiological activity" as conceived by Bellamy, Jordan and King. These factors have to do with the difference between differentiation metabolism and proliferation metabolism, for these observations demonstrate that pigment accumulates in regions of differentiation, but does not accumulate in regions of proliferation. While both these processes involve "oxidation" and "physiological activity," the accumulation of pigment in connection with the one and not with the other shows that the physiological processes must be fundamentally different in the two cases.

In differentiation there is a building up of structures that render the protoplasm more complex. Accompanying the building up of these relatively permanent structures of the cell, by which differentiation is determined, is a certain amount of wear and tear in the protoplasm itself, and this must involve both oxidation and reduction processes. Among the products of these processes of "wear and tear" would be the mother substances of pigment. The metabolism of proliferating cells, however, does not result in the building up of complex, relatively permanent structures in the protoplasm. On the contrary, according to Child (1915) mitosis involves dedifferentiation in the cytoplasm. Proliferation, therefore, must lack the "wear and tear" processes that are characteristic of differentiation, and for that reason lacks the function of pigment production.

Bearing upon the question of the relation between differentiation and dedifferentiation, Child (1915) says: "Cells which divide rapidly do not undergo any great degree of differentiation, and the cells which resume division after undergoing differentiation first undergo a greater or less degree of dedifferentiation." Therefore, in embryonic cells which are undergoing rapid proliferation, such as

those of the ventricular region of the central nervous system of the embryo, the slight differentiation metabolism which may be taking place must be counterbalanced by the predominating processes of dedifferentiation. In such relations differentiation and dedifferentiation must be conceived as antagonistic processes, and the antagonism between these processes must be conceived as involving all that has to do with the substances of the "pigment complex." Any substances of the "pigment complex" that may arise during the resting phase of the cell might become dedifferentiated in the following mitosis. This view receives support from Child's (1915) work on flat worms, in which he shows conclusively that in dedifferentiation highly differentiated tissue structures actually disappear.

The application of this principle of antagonism to the development of *Amblystoma* during the period under consideration explains why mitosis occurs very rarely or not at all in the myotomes which are undergoing rapid differentiation and in the rapidly differentiating regions of the central nervous system. It renders intelligible, also, the polarity of the amphibian egg with reference to pigmentation. Bellamy (1919) considers that the polarity of the frog's egg is determined by the relation of the egg to the blood supply. He says: "This polarity is marked by the localization of most of the protoplasm in the pigmented hemisphere, by the eccentricity of the nucleus, and by the distribution of the pigment." He holds, also, that "local increase of activity results in the formation or the increase of pigment, and local decrease in activity results in diminution of pigment." However, the results of the writer's studies show conclusively that the term "activity" is wholly inadequate to indicate the real nature of the processes under consideration. The conception of polarity as the localization of differentiation metabolism renders the problem of polarity of the amphibian egg intelligible from the point of view of the writer, for yolk is produced in the cytoplasm through differentiation metabolism, and it is necessary that this process take place in the region of oxygen and food supply. But this differentiation metabolism involves the production of the substances of the pigment complex, and in the presence of abundant oxygen they readily become transformed into pigment. The localization of pigment in the egg is, therefore, determined by external conditions as Bellamy proposed, but its origin is specifically involved in the process of differentiation.

CONCLUSIONS.

1. The pigment that is characteristic of amphibian embryos arises in the cytoplasm from colorless granules which are considered to be chromogen and which represent a pigment complex made up of (1) substances that arise in excess from digestion of the yolk, (2) intermediary products of anabolic phases of metabolism, and (3) products of catabolic phases of metabolism.

2. This pigment cannot be unconditionally classified as either melanin or lipochrome, but is regarded as a waste pigment comparable to the bile pigments.

3. This embryonic pigment is an indicator of metabolism that is characteristic of tissue differentiation, as opposed to metabolism that is characteristic of all cell proliferation.

4. In the light of pigment formation, differentiation metabolism and proliferation metabolism are regarded as fundamentally antagonistic processes in development.

BIBLIOGRAPHY.

BELLAMY, A. M. 1919. Differential susceptibility as a basis for modification and control of early development in the frog. Biological Bulletin, vol. XXXVII, No. 1, p. 312.

CHAMPY, G. 1911. Recherches sur l'absorption intestinale et le rolé des mitochondries dans l'absorption et la secretion. Arch. d'anat. mic. XIII, p. 55.

CHILD, C. M. 1915. Senescence and rejuvenescence.

CIACCIO, C. 1915. Über Autooxydation der Lipoidstoffe und über Pigmente. Biochem. Zeit., 69, p. 313.

COGHILL, G. E. 1914. Correlated anatomical and physiological studies of the growth of the nervous system of Amphibia, No. 1. Jour. Comp. Neur., vol. 24, p. 163.

1915. Preliminary studies on intracellular digestion and assimilation in amphibian embryos. Science, n. s., vol. XLII, No. 1080.

1916. Correlated anatomical and physiological studies of the growth of the nervous system of Amphibia, No. 11. Jour. Comp. Neur., vol. 26, p. 247.

DOLLEY, D. H., and GUTHRIE, F. V. 1921. The pigmentation of heart muscle. Jour. Med. Res., vol. XLII, p. 289.

DYSON, W. 1911. An investigation on cutaneous pigmentation in normal and pathological conditions. Jour. Path. and Bact., XV, p. 298.

HUECK, W. 1912. Pigmentstudien. Beitr. z. pathol. Anat. u. z. allg. Pathol. 54.

JENKINSON, J. W. 1914. The relation between the structure and the development of centrifuged eggs of the frog. Quart. Jour. Micro. Science; April.

JORDAN, E. O. 1893. The habits and development of the newt. Jour. Morph., vol. 8.

KING, H. D. 1902. The gastrulation of the *Bufo lentiginosus*. Amer. Nat., vol. 36, p. 527.

LUBARSCH, O. 1902. Uber fetthaltige Pigmente. Cent. f. allg. Path. u. path. Anat. 13, p. 290.

McCLENDON, J. F. 1909. Cytological and chemical studies of centrifuged fro eggs. Arch. Ent. Mech., 27.

MacLEOD, J. J. R. 1922. Physiology and biochemistry in modern medicine Fourth edition.

PALMER, L. S., and ECKLES, C. H. 1914. Carotin: the principal natural yellow pigment of milk fat; its relation to plant carotin and the carotin of the body fat, *corpus luteum* and blood serum. Jour. Phys. Chem., vol. 17 p. 191.

PALMER, L. S. 1916. The physiological relation of the plant carotinoids to the carotinoids of the cow, horse, sheep, goat, pig and hen. Jour. Biol Chem., vol. 27, p. 27.

SCHULTZ, O. T. 1912. The formation of pigment by the dermal chromato phores. Jour. Med. Res., vol. 26.

SCHMIDTMANN, M. 1920. Pigmentstudien. Virchow's Arch. f. pathol. Anat u. Physiol. 227.

SMITH, D. T. 1920. The pigmented epithelium of the embryo chick's ey studied *in vivo* and *in vitro*, with special reference to the origin and de velopment of melanin pigment. Johns Hopkins Hospt. Bulletin, vo XXXI, p. 239.

VON SZILY, A. 1911. Uber die Entstehung des melanotischen Pigments i Auge der Wirbeltierembryonen und in Chorioidealsarkomen. Arch. micro. Anat. Bd. 77, p. 87.

WAGNER, K. 1910. Die Herkunft des Eipigmentes der Amphibien. Zoolog ischer Anzeiger. 35, p. 638.

WHIPPLE, G. H. 1921. Pigment metabolism and regeneration of hemoglobi in the body. Arch. Int. Med., vol. 29, p. 711.

DESCRIPTION OF FIGURES AND PLATES.

REFERENCE LETTERS: *pb*=pigment body. *pg*=pigment granules. *n*=nucleus. *yg*=y
globule. *s*=strands of pigment granules.

FIGURES I, II, III, IV.

FIGURE I. An optical projection of the pigment bodies in a nonmoti
embryo as viewed from the side of the (*a*) third myotome, (*b*) tenth myoton

FIGURE II. Projection of an early embryo similar to figure I, except in ad
tion it contains the projection of (*c*) the eighteenth myotome.

FIGURE III. Projection of a coil-stage embryo similar to figure II.

FIGURE IV. Projection of an early swimming-stage embryo similar to figu
II, except that (*d*) represents the twenty-fourth myotome.

FIGURES I, II, III, and IV.

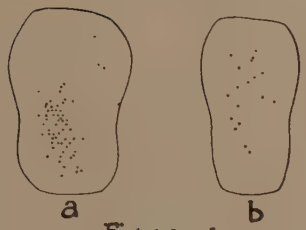

Figure I

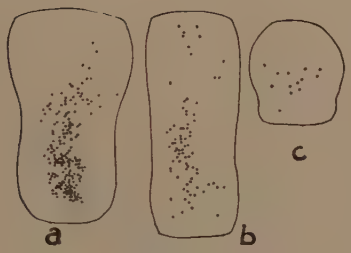

Figure II

Figure III

Figure IV

FIGURE V.

Figure V is a reproduction of drawings of sections taken at different levels of the central nervous system of the various stages, noting the location of the areas of abundant pigmentation by stippling on one side only. Row I was made from a nonmotile-stage embryo; row II from an early flexure-stage embryo; row III from a coil-stage embryo; row IV from an early swimming-stage embryo. Column 1 was taken at the level of the V root; column 2 at the level of the VII root; column 3 at the level of the IX root; column 4 from the spinal cord at the level of the third myotome; and column 5 from the spinal cord at the level of the eighth myotome.

FIGURE V.

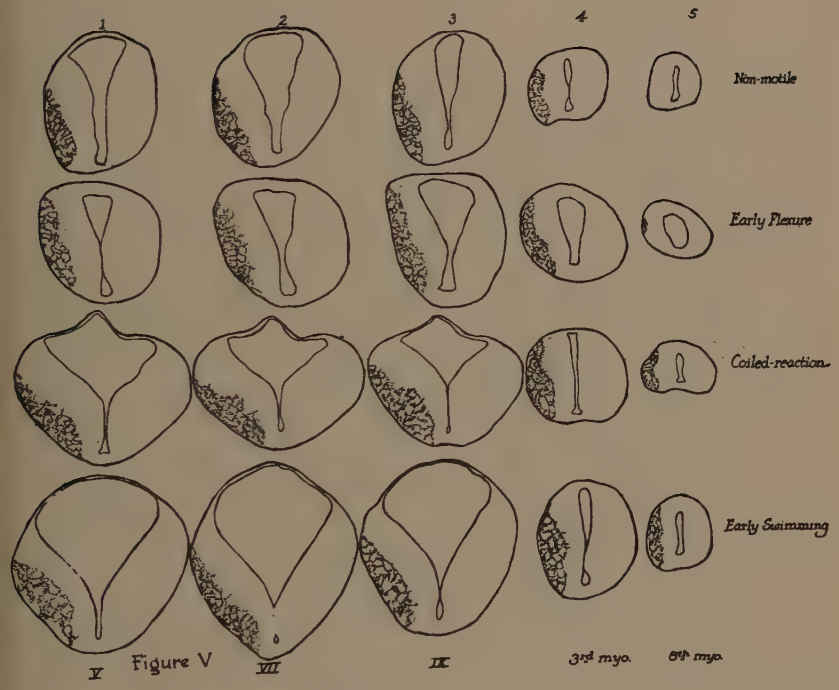

Figure V

PLATE XII.

A photomicrograph (× 800) of a frontal section of the third myotome taken through the middle, dorsoventrally, of an embryo of the early swimming stage fixed in Bouin's solution and stained with Janus green and neutral red. Pigment granules appear rather indistinctly about the yolk globules and the nuclei. The pigment bodies are distributed chiefly near the middle of the myotome longitudinally. They appear as perfectly opaque objects. Four of them lie near the middle of the figure. Two others, smaller than those in the middle of the myotome, lie in the upper part of the plate, one to the left and the other to the right. The striations of the myofibrils accurately represent the degree of differentiation in the contractile tissue of the myotome at this stage in development.

PLATE XII.



PLATE XIII.

A photomicrograph (× 850) of a section taken from the dorsal portion of the tenth myotome of a nonmotile stage embryo. The cells are radially arranged about the center of the myotome. The pigment granules occur in the central part of the myotome. S represents strands of granules extending from ends of nuclei toward the center of the myotome. Yolk globules (yg) are faintly visible and some have pigment granules on their surface. The embryo was fixed in Bouin's fluid and stained with neutral red and Janus green.

PLATE XIII.

PLATE XIV.

This is a photomicrograph (× 440) of a section in frontal plane of the tenth myotome of an embryo of the early swimming stage. The section was taken from the dorsal portion of the myotome. The fixative was corrosive sublimate and acetic acid and the stain was alum carmine and Lyons blue. No pigment granules are visible at this magnification. A row of nuclei can be observed at either end of the myotome. The pigment bodies (pb) are mostly located near ends of nuclei.
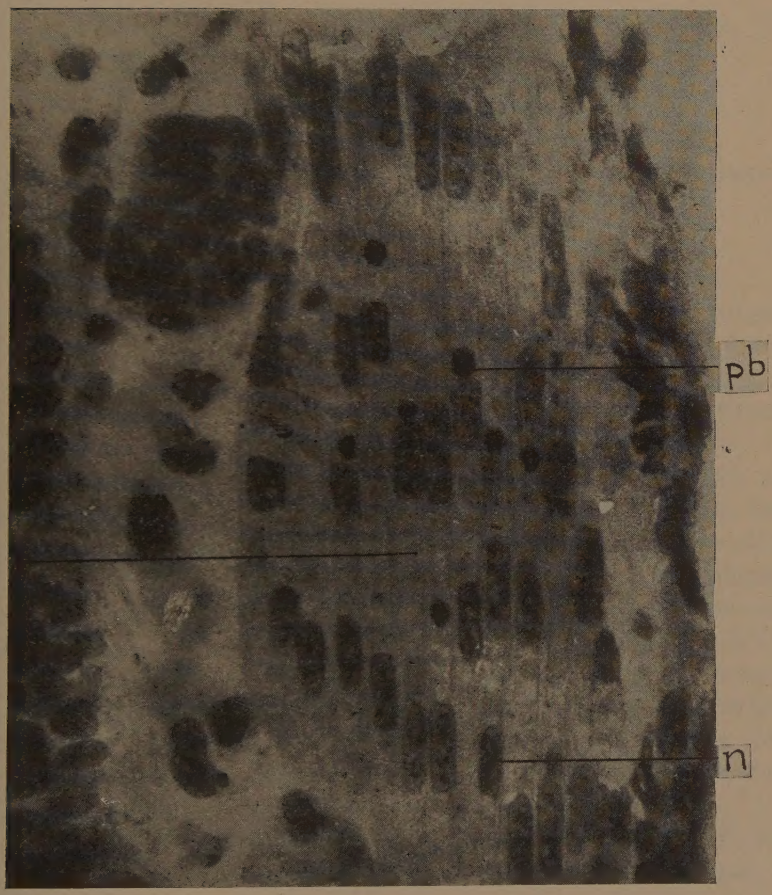
PLATE XIV.